

Evaluation of Ocular Manifestations Treatment Outcome of Allergic Fungal Pan Sinusitis

Sharanabasamma M¹, Prasanth K²

Abstract

Aims: To know the incidence and treatment outcome of various ocular manifestations of Allergic Fungal Pan Sinusitis. **Methodology:** A prospective study was conducted in a medical college hospital in south India for a period of 2 years which included all the cases of Allergic Fungal Pansinusitis presented to the hospital. The cases were diagnosed by Bent-Kuhn criteria. The cases with ophthalmologic involvement were included in the study. CT scan of PNS, brain, orbit were done and the disease extent was noted. Cases with eye involvement were planned for surgical debridement after an initial prednisolone oral 1mg/kg over 2 weeks. Surgical debridement was done endoscopically by a team of ENT surgeon, Oculoplastic surgeon and neurosurgeon. Histopathologic examination was done. Post-surgery the steroids were tapered over 2 weeks. Post-operative follow up was done every day for first week followed by weekly once till a month and every 6 monthly once for a year in the form of clinical examination, CT scan was repeated after a week during post op period. In cases with suspected recurrence CT PNS was performed. Their outcomes were analyzed. **Results:** 6 cases (33%) had ocular involvement. Proptosis was the most common (28%) finding followed by epiphora(22.2%), ophthalmoparesis (22.2%), diplopia (22.2%), ophthalmoplegia (11.%), complete loss of vision (5%). Surgical intervention led to early recovery in proptosis followed by others except with PL -ve case. **Conclusion:** Early treatment in AFPS prevents vision loss and has better outcomes.

Keywords: Allergic Fungal Pan Sinusitis; Proptosis; Epiphora.

Introduction

Allergic fungal sinusitis a non-invasive Pansinusitis that occurs in young immunocompetent individuals, with a strong history of atopy and elevated levels of total immunoglobulin IgE and peripheral eosinophilia. It is histologically characterized by the presence of allergic mucin and scattered fungal hyphae [1]. It was Young et al who first described allergic fungal sinusitis in 1978. They described a case with pan sinusitis with bone erosion [2]. The condition "Allergic fungal sinusitis" as a clinical entity was described in 1981 by Millar et al [3]. Allergic fungal sinusitis is a noninvasive, but vigorous, inflammatory response to mold that occurs in immunocompetent patients with chronic sinusitis and nasal polyposis (Fig. 1).

It typically occurs in patients who have a history of atopic disease [4]. In the sinus cavity thick fungal debris and mucin having carbohydrate-rich glycoprotein develops during the course of this disease [4]. This mucin is characteristically known as "Allergic mucin". Patients with allergic fungal sinusitis commonly suffer from asthma [5]. It is IgE mediated.

Diagnostic criteria for allergic fungal sinusitis (Bent-Kuhn criteria)

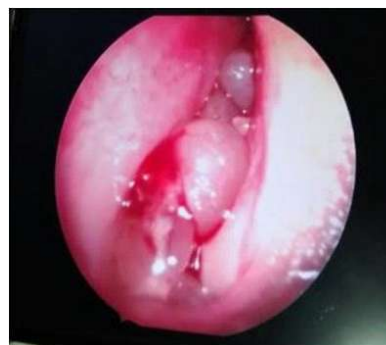

Fig. 1: Endoscopic picture showing polyposis in nasal cavity

Author Affiliation: ¹Associate Professor ²PG student
Navodaya Medical College, Raichur, Karnataka 584103, India.

Corresponding Author: Prasanth K, PG student Navodaya
Medical College, Raichur, Karnataka 584103, India.

E-mail: santhuyadav.md@gmail.com

Received on 11.09.2018, Accepted on 01.10.2018

1. Gross production of eosinophilic mucin containing non-invasive fungal hyphae.
2. Nasal polyposis.
3. Characteristic radiological findings.
4. Immuno competence.
5. Allergic mucin.

Clinical findings in these patients include:

1. Signs of nasal mucosal inflammation
2. Nasal polyposis
3. Facial disfigurement
4. Orbital abnormalities in form of proptosis, epiphora and visual Loss.

Various ophthalmic manifestations of allergic fungal sinusitis include proptosis, diplopia, blepharoptosis, epiphora, ophthalmoplegia, orbital abscesses and rarely visual loss [6]. The pathophysiology of visual loss in patients with allergic fungal sinusitis could be either compression of the optic nerve directly or indirectly or by optic neuritis.

Radiological characteristics of allergic fungal sinusitis:

1. Classically asymmetrical involvement of paranasal sinuses are seen in plain radiographs and CT imaging.
2. Bone erosion with extension of the disease to adjacent areas seen due to pressure effect [7].
3. Sinus expansion with the presence of bone erosion [8].
4. Heterogenous areas of signal intensities in sinus cavities filled with allergic mucin is seen in CT imaging. This is due to accumulation of heavy metals like iron and manganese.
5. 'Double density' sign is usually caused by the dense inspissated eosinophil-rich extra mucosal allergic mucin

This study was undertaken to know the incidence and treatment outcomes of various ocular manifestations of Allergic Fungal Pan Sinusitis.

Materials and Methods

A prospective study was done in a medical college hospital after obtaining ethical clearance from the institute. The study included 18 cases which were diagnosed to have Allergic Fungal Pan Sinusitis from 2016-18. Patients had history of gradual nasal obstruction, h/o allergy, previous sinus disease. Some of the patients were diagnosed by otorhinolaryngology department and were

referred to us to rule out any ocular manifestations. Some patients presented directly to Ophthalmology OPD with ocular complaints resulting because of AFPS. On clinical suspicion of AFPS when history was elicited they also had h/o suggestive of allergy and chronic sinus disease. They were also examined by ENT surgeon. The mucin was sent for microscopic examination to look for presence of eosinophils and charcot-layden crystals. CT scan of Para Nasal Sinuses, Brain and orbit were done in all cases. The diagnosis was made based on Bent-Kuhn criteria and analysis of CT scan reports of these patients. Those cases with ophthalmic involvement were studied for various features. Treatment was planned according to the manifestations. All the cases were treated with oral prednisolone 1mg/kg body weight for 2 weeks along with nasal steroid spray followed by which debridement was done through endonasal approach which was lead by a team of ENT Surgeon, Oculoplastic surgeon and neurosurgeon. Histopathological examination was done. Following surgery the oral steroids were continued for 2 more weeks in tapering dose. Follow up was done every day for first week followed by weekly once till a month and every 6 monthly once for a year in the form of clinical examination, CT scan was repeated after a week during post op period. In cases with suspected recurrence CT PNS was performed. Their outcomes were analyzed.

Results

Out of 18 cases which were diagnosed with AFPS only 6 (33%) cases had ophthalmic manifestations. Out of 18 patients 10 (55.5%) were male, 8 (44.4%) were females. Among the individuals with ocular involvement males were 4 in number (0.22%) and females were 2 (0.11%). The patient with youngest age was 15yrs and oldest was 38 yrs. The disease was unilateral in 11 cases (61.1%) and bilateral in 7 cases (38.8%).

Ophthalmic involvement was unilateral in all cases surprisingly (Fig. 2,3,4).

Finding followed by Proptosis was the most common (28%) epiphora (22.2%), ophthalmoparesis (22.2%), diplopia (22.2%), ophthalmoplegia (11%), complete loss of vision (5%) (Table 1).

Ct scan showed bilateral nasal and sinus involvement in 11 cases and unilateral in 7 cases. (Fig. 5,6). Orbital involvement was seen in 6 cases. It was unilateral in all cases. Only 1 case had involvement of optic nerve and intracranial extension (Fig. 7).

Following the surgery which included debulking of the granuloma, it was observed that proptosis (Fig. 3,8), epiphora were recovered early (in 3 days). While ophthalmoparesis, ophthalmoplegia recovered over a period of 2 weeks. There was no gain of vision in the case with visual loss.



Fig. 2: Right eye axial proptosis sec to AFPS

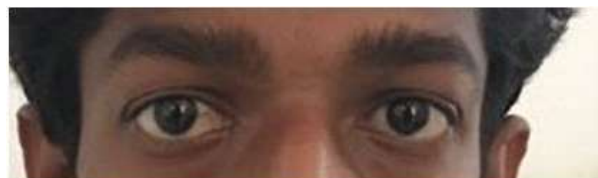

Fig. 3: Right eye Proptosis reduced postoperatively

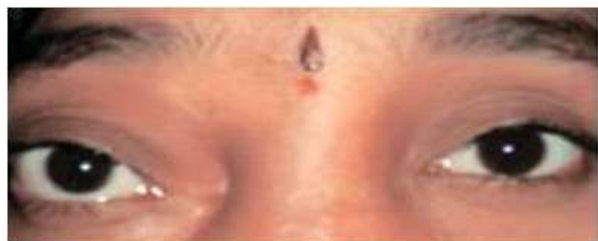

Fig. 4: Eccentric Proptosis secondary to AFPS

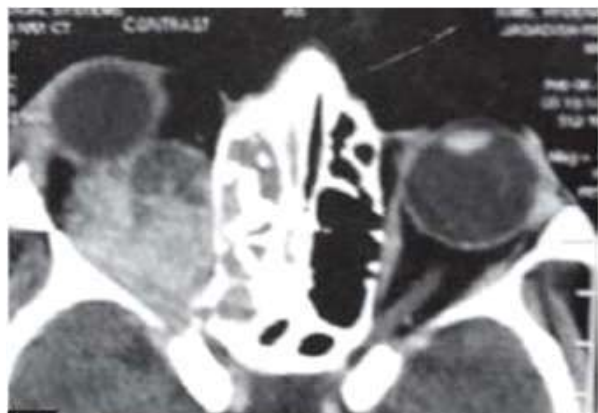


Fig. 5: Involvement of the anterior and posterior ethmoid sinuses and an orbital extension

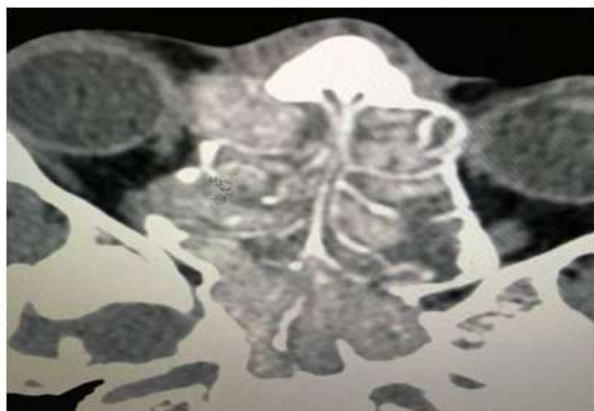


Fig. 6: CT scan showing bilateral sinus involvement with breach of rt orbit medial wall with medial rectus impingement

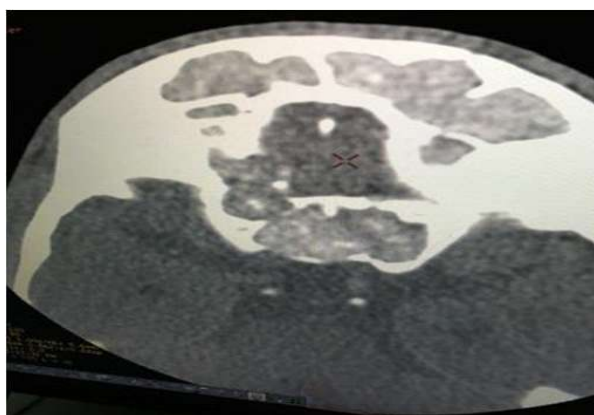


Fig. 7: CT scan showing intra cranial involvement

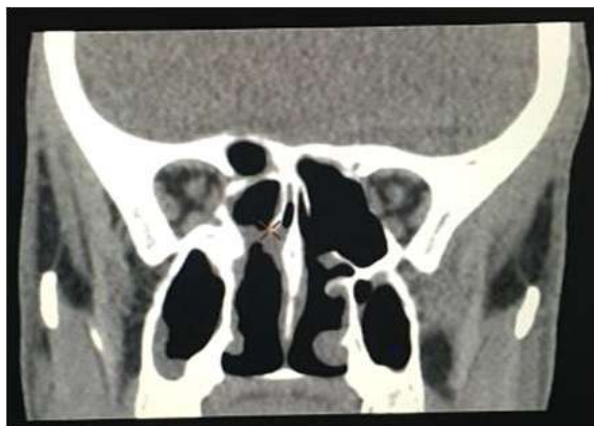

Fig. 8: Post Op CT scan showing enlarged empty PNS

Table 1: Various ocular manifestations of AFPS

S.No.	Ocular manifestations of AFPS	Percentage (n=18)
1	Proptosis	28%
2	Epiphora	22.2%
3	Ophthalmoparesis	22.2%
4	Diplopia	22.2%
5	Ophthalmoplegia	11%
6	Complete loss of vision	5%

Discussion

Allergic Fungal Pan Sinusitis is an allergic response to the fungal antigens in sinonasal cavities. It occurs in young immunocompetent people with h/o sinus disease, atopy and asthma. There occurs pressure necrosis and erosion of the sinus walls because of this granuloma there by leading to expansion of sinus walls, extension of this granuloma into other neighbouring cavities. Orbital involvement is less common complication of this disease. And orbital involvement usually occurs due to breach in the medial orbital wall.

In our study we found the incidence of ocular manifestations of AFPS as 0.33% (6 of 18). In a study by Ali. H et al. [9] the incidence of ocular manifestations in AFPS was 27 out of 60 (0.45%) which was almost similar to that of our study. Male to female ratio is 1.25:1. It is almost similar to that of incidences of study series conducted by Thahim et al. [10] Richard D deshazoin [11] which there was male preponderance. But in study conducted by Scott C Manning [12], Zakirullah et al. [13] there was female preponderance. In our study age of patients ranged from 6 years to 36 years among which majority were in the age group of second decade which was similar to few studies [11,14]. The clinical features depend upon the extent of involvement which can be orbital, intracranial. In our study Proptosis was the most common (28%) finding followed by epiphora (22.2%), ophthalmoparesis (22.2%), diplopia (22.2%), ophthalmoplegia (11%), complete loss of vision (5%) among 18 cases of AFPS. The rest had no ocular involvement. In a study by Zakirulla et al. [13] proptosis was the most common ocular manifestation. Orbits being in close proximity to the sinuses they are the ones to be commonly involved leading to proptosis. Diplopia occurs due to impingement of extra ocular muscles by the granuloma. In one case we had the patient presenting to us with complete loss of vision which was gradual. It was due to the compression of the optic nerve. In the same case there was involvement of anterior cranial fossa which occurred due to breach in the ethmoidal bone.

Unilateral presentation was high in our study similar to studies by Bent & Kuhn [15] Sohail et al. [16] and Thahim et al. [10].

Intra operative findings were extensive nasal polyposis with thick mucin which was of pea nut butter appearance were present. The debrided tissue was sent for HPE which showed fungal hyphae, eosinophils, Charcot laden crystals in all cases. Tissue infiltration is not seen in AFPS in

contrast to invasive fungal diseases because it is the saprophytic growth occurring in the degenerated tissue which occurs because of allergic response elicited due to fungal antigens.

Post-operative recovery was seen for proptosis initially in our study similar to that of study by Ali. H. et al. [9]. there was no recovery of vision in the case with optic nerve compression which remained PL-ve in spite of surgical debridement.

Recurrence was noted in only 2 cases among 18 which occurred at the end of 1 year. It was limited to the sinuses itself for which oral steroids were started and tapered over 3 weeks period after which improvement occurred and there was no need for surgery. The main drawback of our study was that we didn't estimate the serum levels of IgE, which is an important tool in diagnosis due to financial constraints of the patients.

Conclusion

Postoperative oral corticosteroids appear to be effective option, AFPS is a disease involving young and immune competent individuals. It has orbital involvement. Early diagnosis and treatment of Allergic Fungal Pan Sinusitis can lead to the complete recovery from ocular manifestations except for vision blinding effects.

References

1. Torres C, Ro JY, El-Naggar AK Sim SJ, Weber RS, Ayala AG. Allergic fungal sinusitis: A clinicopathologic study of 16 cases. *Hum Pathol* 1996;27:793-9.
2. Young CN, Swart JG, Ackermann D, Davidge-Pitts K. Nasal obstruction and bone erosion caused by *Drechslera hawaiiensis*. *J Laryngol Otol* 1978;92:137-143.
3. Millar JW, Johnston A, Lamb D. Allergic aspergillosis of the maxillary sinuses. *In Thorax* 1981;36:710-710.
4. Coop CA, England RW. Allergic fungal sinusitis presenting with proptosis and diplopia: a review of ophthalmologic complications and treatment. *Allergy Asthma Proc* 2006;27:72-76.
5. Brandwein M. Histopathology of sinonasal fungal disease. *Otolaryngol Clin North Am* 1993;26:949-981.
6. Kirsztrot J, Rubin PA. Invasive fungal infections of the orbit. *Int Ophthalmol Clin* 2007;47:117-132.
7. Kinsella JB, Rassekh CH, Bradfield JL, Chaljub G, McNees SW, et al. Allergic fungal sinusitis with cranial base erosion. *Head Neck* 1996;18:211-17.

8. Lund VJ, Lloyd G, Savy L, Howard D. Fungal rhinosinusitis. *J Laryngol Otol* 2000;114:76-80.
 9. Alizarei AH, Assiri KS. Orbital Complication of Allergic Fungal Rhino-sinusitis. *Int J Clin Case Stud* 2016;1:111. Doi: <http://dx.doi.org/10.15344/2455-2356/2016/111>.
 10. Thahim K, Jawaid MA, Marfani MS. Presentation and management of allergic fungal sinusitis. *J Coll Physicians Surg Pak* 2007;17:23-7.
 11. DeShazo RD, Swain RE. Diagnostic criteria for allergic fungal sinusitis. *J Allergy Clin Immunol* 1995;96:24-35.
 12. Manning SC, Mabry RL, Schaefer SD, Close LG. Evidence of IgE-mediated hypersensitivity in allergic fungal sinusitis. *Laryngoscope* 1993;103:717-21.
 13. Zakirullah, ghareeb nawaz, syed fazle sattar; presentation and diagnosis of allergic fungal sinusitis; *j ayub med coll abottabad* 2010;22(1).
 14. Schubert MS. Allergic fungal sinusitis. *Otolaryngol Clin N Am* 2004;37:301-26.
 15. Bent JP 3rd, Kuhn FA. Diagnosis of allergic fungal sinusitis. *Otolaryngol Head Neck Surg* 1994;111:580-8.
 16. Sohail MA, Al Khabori MJ, Hyder J, Verma A. Allergic fungal sinusitis: Can we predict the recurrence? *Otolaryngol Head Neck Surg* 2004;131:704-10.
-